



▶ [What are Hemorrhoids?](#)

▶ [Hemorrhoid Treatment Options](#)

▶ [Anal Rectal Conditions](#)

▶ [Colon Conditions](#)

▶ [Patient Information](#)

Anatomy - Anus and Rectum

INTRODUCTION

THE ANUS

[The Anorectal Line](#)

[The Anal Valves](#)

[Fascia](#)

THE RECTUM

[The Columns Of Morgagni \(Rectal Columns\)](#)

[Measurements](#)

[The Mucosa](#)

[The Submucosa](#)

[The Musculature of the Rectum](#)

[The Serous Coat](#)

[The Rectal Valves](#)

[The Third Sphincter of O'Beirne](#)

[The Sigmoid](#)

THE EXTERNAL SPHINCTER

[The Subcutaneous Muscle](#)

[The Superficialis Muscle](#)

[The Profundus Muscle](#)

THE CORRUGATOR CUTIS ANI MUSCLE

THE INTERNAL SPHINCTER

THE LONGITUDINAL MUSCLE

MILLIGAN'S SEPTUM

THE ANORECTAL MUSCLE RING

THE ANOCOCCYGEAL LIGAMENT OR BODY

THE LEVATOR ANI MUSCLE

[The Pubococcygeus Muscle](#)

[The Puborectalis Muscle](#)

[The Iliococcygeus Muscle](#)

[The Ischiococcygeus Muscle](#)

THE PELVIC TRIANGLES

THE PERINEOPELVIC SPACES

- The Perianal Space
- The Submucous Space
- The Ischiorectal Fossae
- The Supralevator Spaces (pararectal)
- The Retrorectal Space (Pre-sacral)
- The Rectovaginal Space
- The Anococcygeal Triangle

THE BLOOD SUPPLY TO THE ANORECTAL REGION

THE VASCULAR SUPPLY TO THE RECTUM

THE VENOUS SUPPLY OF THE RECTUM

THE LYMPHATICS

- Anorectal Lymphatics
- The Perineal Group
- The Anorectal Group
- The Extrarectal Group

THE NERVE SUPPLY TO THE ANORECTAL REGION

NEUROPHYSIOLOGY (Defecation Reflex)

BIBLIOGRAPHY

INTRODUCTION

Perhaps the most influential osteopathic proctologists of the twentieth century were Carlton M. Noll and Frank D. Stanton. Presented here, as a tribute to these great men is the written text of Dr. Noll, and the line drawings of Dr. Stanton.

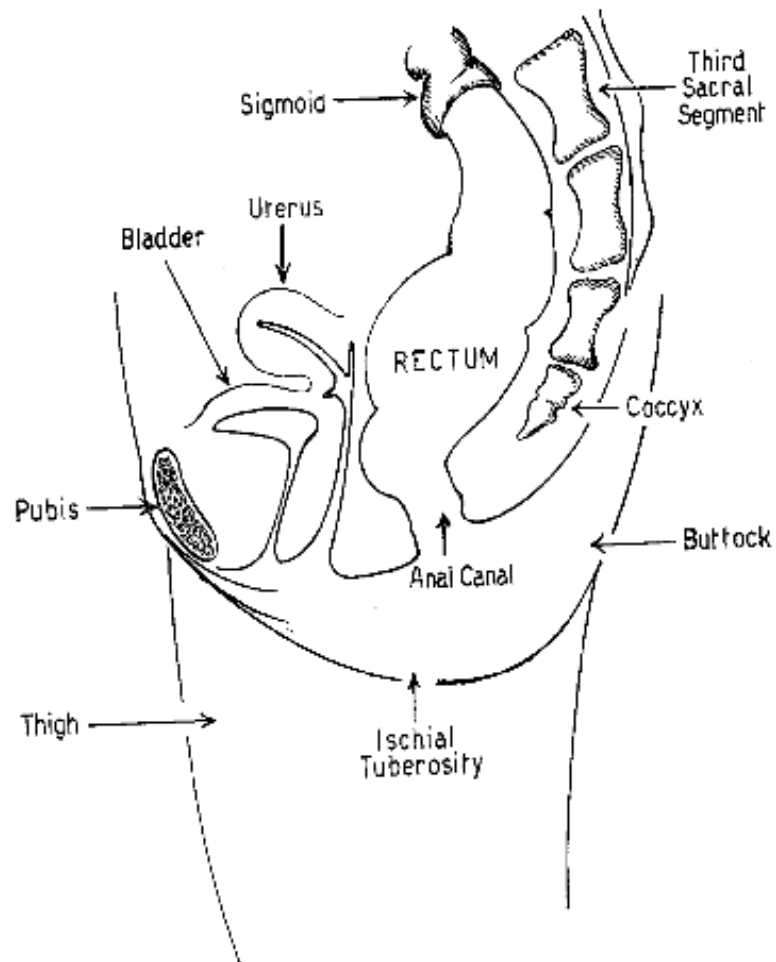


Figure 1: The rectum and anal canal.

top

THE ANUS

The anus is the outlet of the gastro-intestinal tract. (Fig. 1) It is a slit in its resting period. It is expandable, conforming to the size and shape of the fecal content, and it normally varies from 1.2 to 3.5 cm in diameter in the act of defecation. The anus is surrounded by the subcutaneous muscle of the external sphincter (Fig. 2).

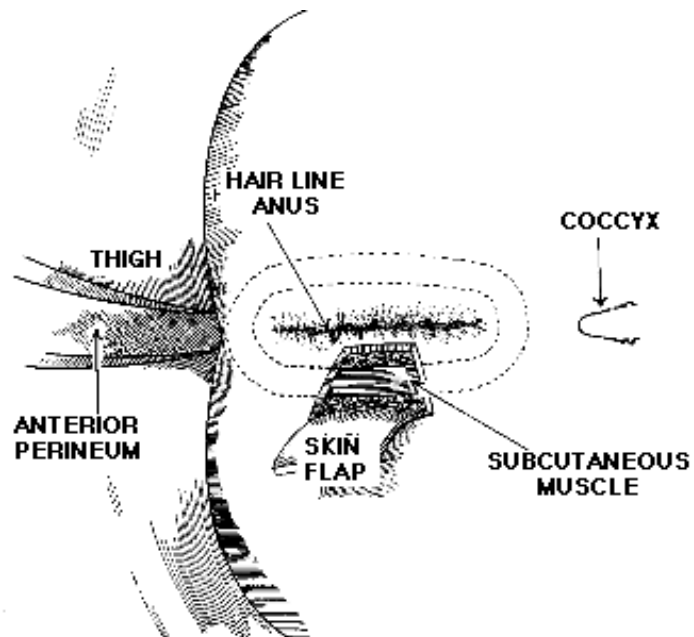


Figure 2: The anus, showing the subcutaneous muscle.

Fibers from the conjoined longitudinal muscle sphincter (Fig. 3) and its fibroelastic extensions pass into, through and around the subpecten with its glands, lymphatics and capillary network that is of great importance in anorectal suppurative processes. This is the zone of anastomoses between the superior hemorrhoidal and inferior hemorrhoidal plexuses, and to a lesser extent, the middle hemorrhoids. The pecten's vascular anastomosis drains freely to either the portal or caval systems. Changes in the nerve supply and lymphatic drainage, also takes place at this zone. The pecten marks the area of greatest narrowing of this region.

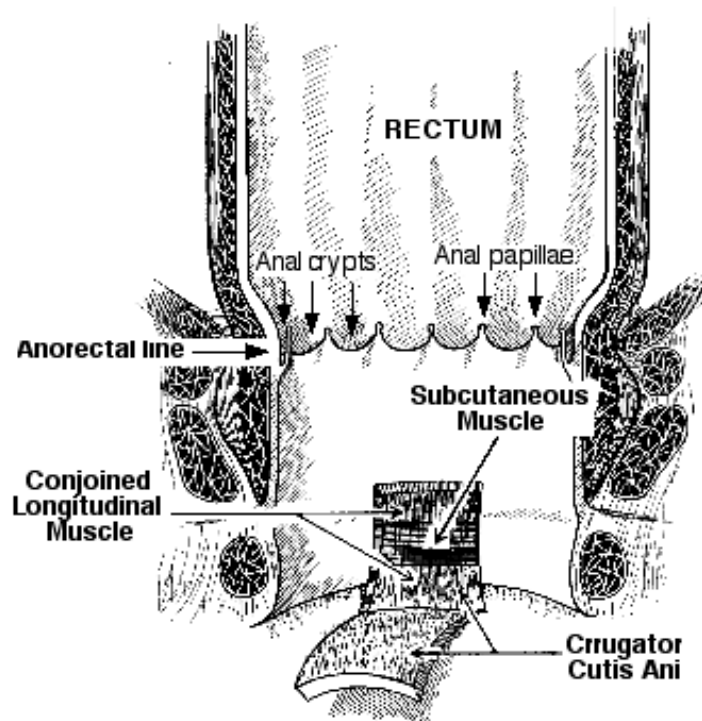


Figure 3: Conjoined longitudinal and corrugator cutis ani muscles.

[top](#)

The Anorectal Line

The anorectal line (dentate, pectinate, valvular, papillary etc.) marks the upper irregular margin of the pecten (Fig. 3). Anal papillae are more often absent than present, but when present, they do not usually arise from the free edges of the anal valves or crypts as some suppose. They correspond usually to the rectal columns of Morgagni (Fig. 4). The tips of the papillae frequently project above the lower margins of the rectal columns and are referred to as anal papillae.

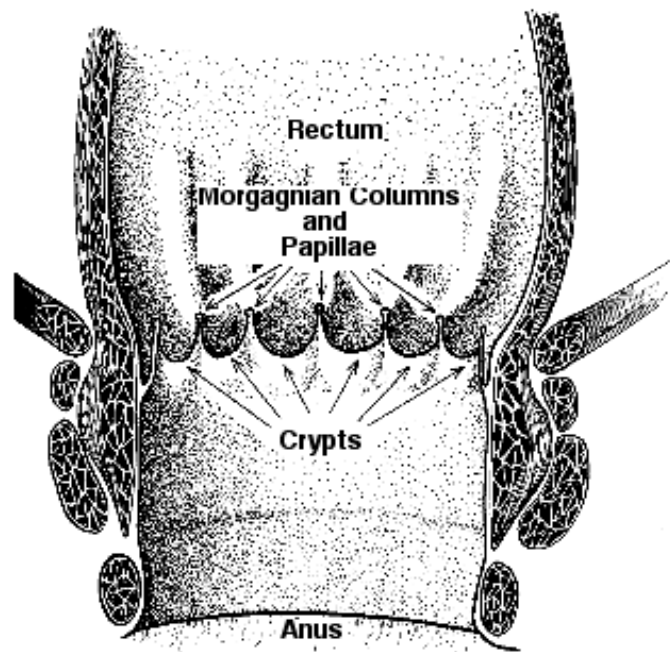


Figure 4: Papillae, crypts and Morgagnian columns.

According to Gorsch, the anal crypts (Fig. 4), a.k.a. anal pockets, sinuses, Saccules of Harner etc.; are tiny recesses projected between adjacent anal columns and behind the anal valves. They vary in number, depth, and shape. The more constant and larger crypts are usually just lateral to the posterior commissure and are regularly described as an etiological factor in anal fissure and fistulae. The blind ends of the crypts extend into the pecten and the proximal open ends are directed toward the rectum.

[top](#)

The Anal Valves

The so-called anal valves are folds of squamous epithelium bridging adjacent anal columns from the free inner wall of anal crypts (Fig. 4). Histologically, the valves are thickened or cornified epidermis, which becomes continuous with the rectal columnar epithelium projected distally between the anal columns into the blind end of the crypts.

[top](#)

Fascia

Gorsch describes the relations of the anal canal in detail. Anteriorly in the male the anal canal is in relation with the perineal body and the accumulated concentrations of fascia at this point. From below and upward, these include the superficial and deep layers of the superficial fascia, Colle's Fascia, at its attachment to the posterior margin of the triangular ligament, in which lie the adjoining superficial transverse perineal muscles of the bulb of the urethra, the superficial and deep layers of the triangular ligament, and finally, the rectourethralis muscle, forming the floor of the prerectal space.

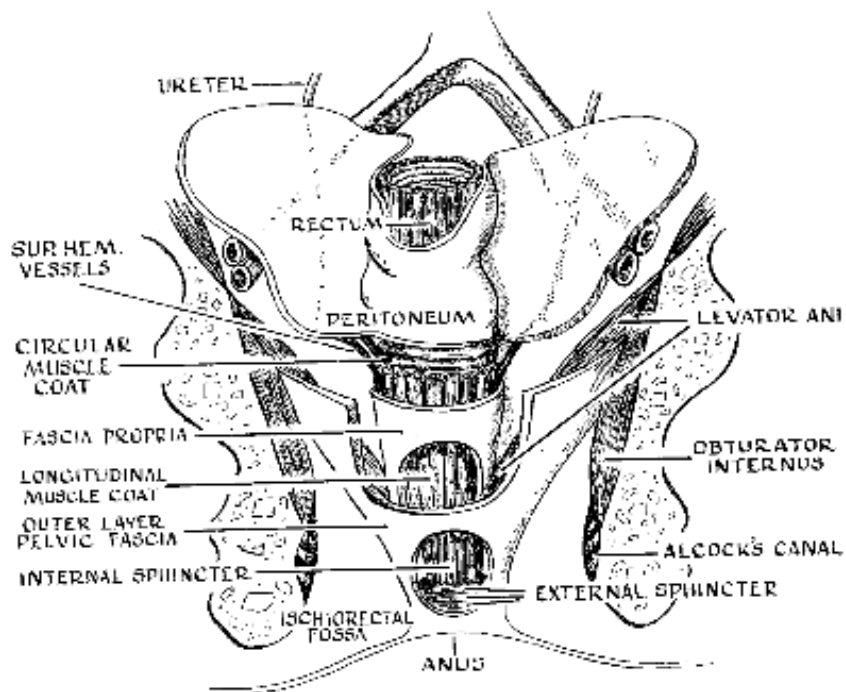


Figure 5: Muscles and fasciae.

In the female, the anal canal lies posteriorly in relation to the sphincter vaginae (Bulbocavernosus) muscle and the ill-defined posterior margin of the triangular ligament, the rectovaginal muscle, which forms the floor of the rectovaginal space (septum), or the prerectal space which is located just above the deep portion of the external sphincter.

Laterally, the anal canal, covered by anal fascia, comes into relation with the wider ischioanal fossae (Fig. 5) with its fibro-cellular matrix. Posteriorly, the anal canal is in relation with the anococcygeal body, which through its muscular and fascial reflections, contributes materially to structural support.

[top](#)

THE RECTUM

Gorsch states that for practical purposes, the rectum may be described as extending from the level of the third sacral vertebral body to the anorectal line. The third sacral corresponds to the termination of a definite mesentery; it marks the point at which there is a change in the blood supply; the level at which the tinea of the sigmoid spread out to reinforce the longitudinal muscle coat; it corresponds to the site of the rectal narrowing to join the sigmoid; it marks the change in color, the capillary pattern the rugosity of the rectal mucosa. From the functional and endoscopic points of view, it may be divided into the sphincteric and ampullary portions. The sphincteric portion corresponds to the annulus hemorrhoidalis, surrounded by the levator ani and the fascial collar from the supra-anal fascia. The ampullary portion extends from the third sacral to the pelvic diaphragm at the insertion of the levator ani.

[top](#)

The Columns Of Morgagni (Rectal Columns)

These are mucosal longitudinal folds formed in the bulbus analis of the primitive rectum and persist as the rectal columns of Morgagni (Fig. 4). These columns act as accommodations for contractions and dilations of the anal canal and the sphincteric portions of the rectum. Histologically, these consist of a somewhat denser muscularis mucosa, with richer lymphatics, vascular, and nerve supply than those of the adjacent intervening rectal wall. Between the columns are the so-called sinuses of Morgagni, which are directly continuous with the crypts.

[top](#)

Measurements

The rectum varies from 10-15 cm in length, while the circumference varies from 15 cm at the

rectosigmoid junction, to 35 cm or more at its widest ampullary portion.
Conformation

The ampulla of the rectum may be roughly pear shaped or balloon shape. Longitudinally, the rectum conforms to the sacral curve. It presents lateral curvatures, which may be quite prominent, and correspond to the indentures opposite the rectal valves. The adult rectum has four well-defined coats: Mucous, Submucous, Muscularis (circular and longitudinal), and Serous (Fig. 6).

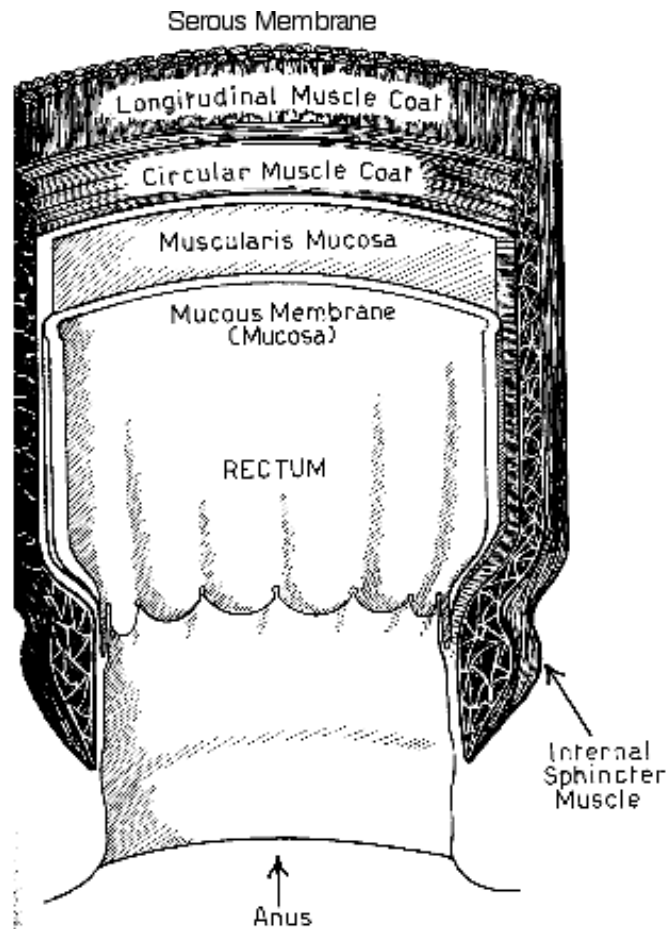


Figure 6: Coats of the rectum.

top

The Mucosa

The mucosa of the rectum (Fig. 6) is thick, darker and somewhat more highly vascularized than any other mucosa in the gastro-intestinal tract. It is more mobile and has a particularly well-developed glandular apparatus, consisting of the mucigenous tubular glands (Lieberkuhn). The epithelial surface of the rectal mucosa is covered by a layer of stratified columnar cells, which assumes a cuboid shape as they go proximally. The mucosa contains abundant lymph follicles situated between the glands of Lieberkuhn. The syncytial or intrafollicular tissue between the glands conveys the lymphatics, nerve plexuses and vascular supply. The deep anal intramuscular glands are found at the anorectal junction.

top

The Submucosa (Muscularis mucosa)

In this region (Fig. 6), the layer underlying the columns of Morgagni, the bulbus terminalis of the superior hemorrhoidal arteries and veins ramify in a supportive syncytial network of elastic and connective tissue, forming the internal or superior hemorrhoidal plexus. This arrangement permits considerable mobility of the area, and at the same time predisposes it to arteriovenous dilation and redundancy. It contains some longitudinal muscle fibers and is particularly rich in lymphatic and terminal nerve fibers and plexuses.

[top](#)

The Musculature of the Rectum

The rectum like the colon has inner circular and outer longitudinal layers of muscle (Fig. 6). The inner circular layer has a wing-like arrangement in which successive muscular bundles sweep fan-like from the indentations, corresponding to the valves over the lateral bulb-like expansions of the rectum. At its lower extremity, about 3-4 cm from the anal margin, the internal muscle becomes thicker and finally terminates in the well defined internal anal sphincter, which is partially encircled by the deeper layers of the external sphincter.

The outer longitudinal tunic of the rectum is formed by an expansion of the colonic tinea at the termination of the sigmoid colon. The expansion of the tinea forms a more or less diffuse fibromuscular coat, which continues down on the rectum as definite anterior and posterior banks. (Fig. 5) These become more muscular at the anorectal junction and fuse with the rectococcygeus, rectourethralis, and rectovaginalis. At the levator-rectal junction, the longitudinal muscle joins with, and is reinforced by the fibroelastic extensions from the levator, forming the conjoined longitudinal muscle. The rectal valves appear to be points of anchorage for muscle coordination.

[top](#)

The Serous Coat

The peritoneal coat (Fig. 6) is contained in this coat and continues from the sigmoid, is reflected over the anterior surface of the rectum, and into the interval between the bladder and uterus, forming the rectovesical or uterine pouches. Laterally the peritoneal folds are reflected diagonally upward and backward to form the pararectal fossae and the leaves of the mesorectum and sigmoid. Anteriorly, they form the paravesicular fossae.

[top](#)

The Rectal Valves

The rectal valves are crescentic plications, which have a definite structure, including the circular muscle coat of the bowel wall. In the strict sense they are not valves, and the degree to which they are able to function as such, is still debatable. Occasionally, the valves are absent.

The valves are quite variable in number, location and degree of development. Usually there are three: an inferior, middle and superior but occasionally there are five. The inferior valve is usually located in the left posterior quadrant from 2.5 to 3.5 cm above the anal margin. The middle valve, usually more prominent and more constant in location, is situated over the base of the bladder or a little to the right, about 5-9 cm from the anal margin. It is referred to as the plica transversalis of Kohlrousch. The superior valve lies 3-4 cm above the middle valve.

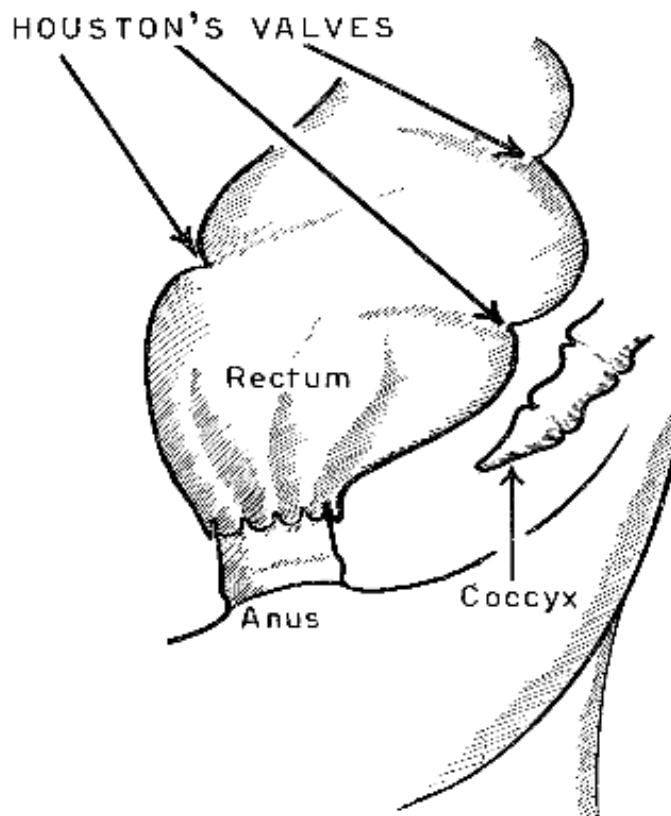


Figure 7: Houston's valves

According to Stanton, Houston described the rectal valves which bear his name. These valves are reflections of the rectal mucosa, which contain some fibers of the circular muscle coat of the rectal wall. They lie obliquely and transverse to the length of the rectum and project into the length of the rectal lumen (Fig. 7). Their purpose seems to be, to serve as steps or spiral supports to modify the flow of the feces as they descend into the lower rectum.

There are usually three, sometimes four, Houston's valves. The lowest valve is located to the left of the midline and extends somewhat anteriorly. It is a convenient landmark in that it marks the usual limit of the downward reflection of the peritoneum anteriorly. The next valve is on the right side. This valve is said by some authorities to be on the level of the pouch of Douglas in the female, and the rectovesical pouch in the male.

[top](#)

The Third Sphincter (Sphincter of O'Beirne)

At a distance varying from 2-3 cm above the superior valve, the lumen of the rectum decreases in caliber to conform to that of the sigmoid (recto-sigmoid junction). At the site of this narrowing, a more or less definite increase in the circular muscular coat of the bowel is regularly described as the third sphincter, or the Sphincter of O'Beirne, having a special function in the act of defecation. It is not a true sphincter, but similar in action.

[top](#)

The Sigmoid

The sigmoid is that portion of the large bowel that extends approximately from the upper border of the left psoas muscle to the proximal end of the rectum (Gorsch). It is of proctologic interest because it is accessible to endoscopic examination. The sigmoid may vary from 12-84 cm. Adults average 40 cm while children average 18 cm. The mucosa and Submucosa differ only from the rectum in that both are not so richly endowed with vascular and glandular structure. The muscle layers consist of an inner circular and an outer longitudinal tunic, which follow the general arrangement of the colonic musculature.

[top](#)

THE EXTERNAL SPHINCTER

The external sphincter is formed by three striated muscles (Fig. 8):

1. The Subcutaneous
2. The Superficialis
3. The Profundus

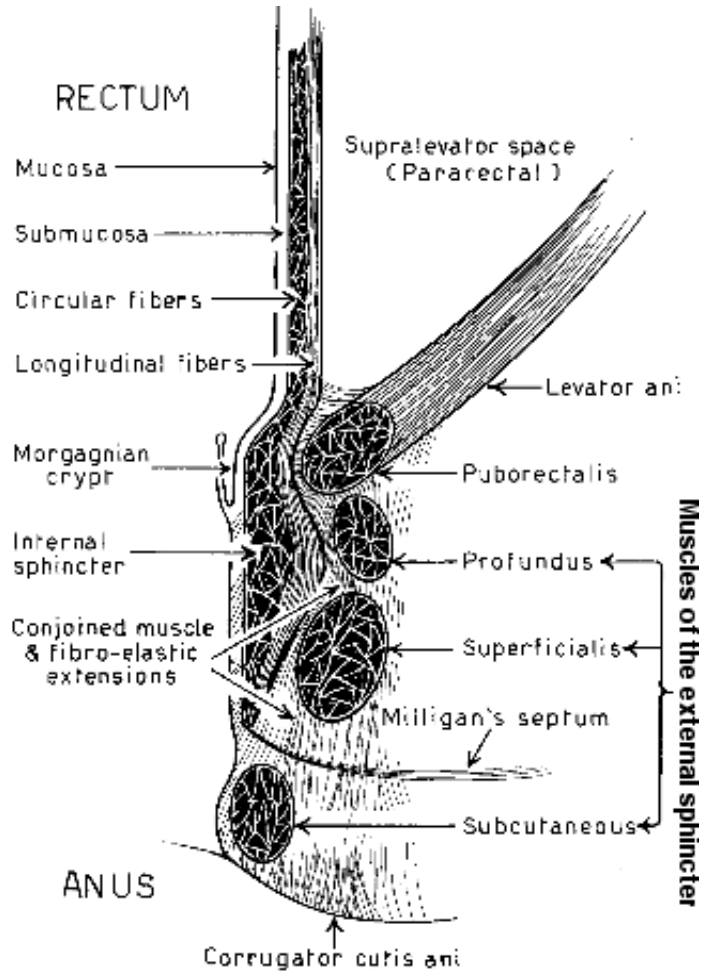


Figure 8: Coronal section showing anorectal muscles.

[top](#)

The Subcutaneous Muscle

This portion of the external sphincter (Fig. 9) is situated immediately below the transitional anal skin (transiderm). The bulk of the muscle is usually annular and disposed somewhat to or on the same longitudinal plane with the internal sphincter. It forms the lower wall of the anal canal. Occasionally it presents small posterior extensions, continuous with the strong converging legs of the superficialis muscle. Anteriorly, it may decussate with the bulbocavernosus and the retractor scroti. In the female anteriorly, it is continuous with the sphincter vaginae.

The upper and inner margin is separated from the lower edges of the internal sphincter by prominent insertions of the fibroelastic extensions of the conjoined longitudinal muscle. This forms the intersphincteric line. The subcutaneous muscle lies in a septal network formed by the fibro-elastic muscle, and interweaves with the subcutaneous, presenting support. These terminal extensions into the skin form the corrugator cuis ani.

[top](#)

The Superficialis Muscle

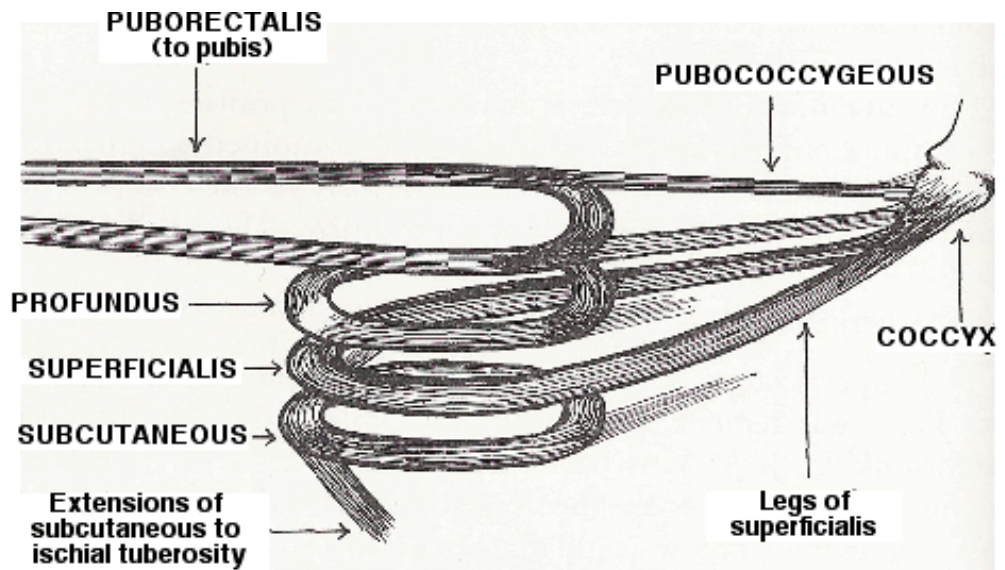


Figure 9: Schematic drawing showing the posterior pull of the superficialis muscle and the anterior pull of the puborectalis muscle, in the conscious control of the rectal outlet.

This is an elliptical band of muscle fibers (Fig. 9), which embraces the anal canal at the level of the internal sphincter. It is the largest, longest and strongest portion. Arising from the sides of the coccyx and forming the important muscular component of the anococcygeal body, its diverging halves surround the mid-portion of the anal canal. In the male anteriorly, they converge and insert into the central tendinous raphe. In the female, they diverge and fuse with the sphincter vaginae. Anteriorly also, crossing fibers extend laterally into the fascial shelf and attach to the ischial tuberosity and adjacent fascia.

In both sexes, the anterior and posterior communicating spaces extend directly above the superficialis fibers, and below the profundus muscle.

[top](#)

The Profundus Muscle

This portion of the external sphincter (Fig. 9) is situated immediately above the superficialis muscle. The fibers are usually annular. Occasionally, uncrossed fibers extend posteriorly to reach the anococcygeal ligament.

Anteriorly, the profundus forms the upper margin of the anorectal muscle ring, but posteriorly the puborectalis muscle forms the upper margin of this ring. The profundus lies in close relation to the legs of the levator and a common crossed arrangement of the entire muscle, extends to the opposite ischial tuberosity on either side.

[top](#)

THE CORRUGATOR CUTIS ANI MUSCLE

This muscle (Fig. 8) represents the terminal insertions of the fibro-elastic extensions of the longitudinal muscle into the anal canal and perianal skin. The extensions seem to penetrate the substance of the subcutaneous muscle as well as passing on either side of this muscle.

[top](#)

THE INTERNAL SPHINCTER

The terminal portion of the circular muscle coat of the rectum gradually thickens to become the component of the internal sphincter. This muscle is surrounded by the superficialis portion of the

external sphincter and forms the entire inner muscular layer of the wall of the anal canal (Fig. 8). Immediately below its lower margin, the internal sphincter is separated from the upper border of the subcutaneous by the prominent insertions of the longitudinal muscle, forming the intermuscular septum of the intersphincteric line. Overlying the internal sphincter is the pecten, covered by squamous epithelium with subjacent areolar tissue containing lymphatics, crypts, preformed anal glands, capillaries and nerves.

The anal canal measures from 1.5-2.5 cm anteriorly in length, 2-3 cm in length laterally, and 3-4 cm in length posteriorly.

[top](#)

THE LONGITUDINAL MUSCLE

An attenuation of the anterior and posterior longitudinal bands, and tinea of the sigmoid form the longitudinal muscle coat of the rectum, which spread out to surround the inner circular muscle coat. At the anorectal junction, the longitudinal coat becomes fibro-elastic in character, fuses with the levator and fascial extensions and becomes the longitudinal muscle (Fig. 10). This fascial arrangement fixes and protects the anal canal and acts as a tendon sheath for the divisions of the anal musculature.

[top](#)

MILLIGAN'S SEPTUM

Milligan describes a septum of fascia, Milligan's Septum (Fig. 10), which extends from the lower border of the internal sphincter muscle and turns outward below the superficialis and above the subcutaneous muscles, to be inserted into the ischial tuberosity and the skin. Posteriorly, the septum is incomplete.

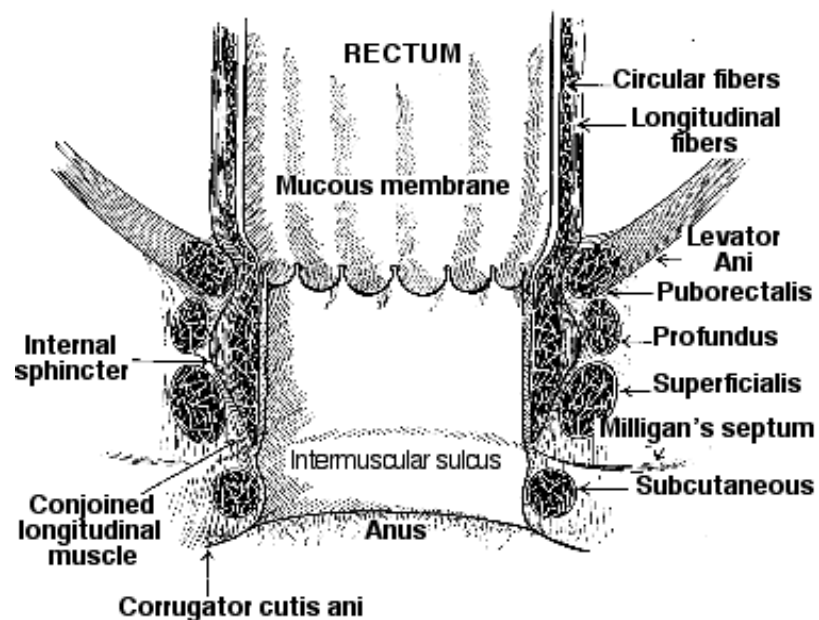


Figure 10: The intermuscular sulcus.

According to Stanton, The intermuscular sulcus (Fig. 10) readily palpated in the anal canal is located at the level of Milligan's septum, in the space between the subcutaneous and internal sphincter muscles. It is a depression formed by the retraction of the skin of the canal by the pull of the insertions of the conjoined longitudinal muscle. It encircles the canal and serves as a landmark in diagnosis and treatment.

[top](#)

THE ANORECTAL MUSCLE RING

The levator ani muscle, in conjunction with the profundus portion of the external sphincter, forms a combined musculo-fascial ring (Fig. 11), which completely surrounds the anorectal junction.

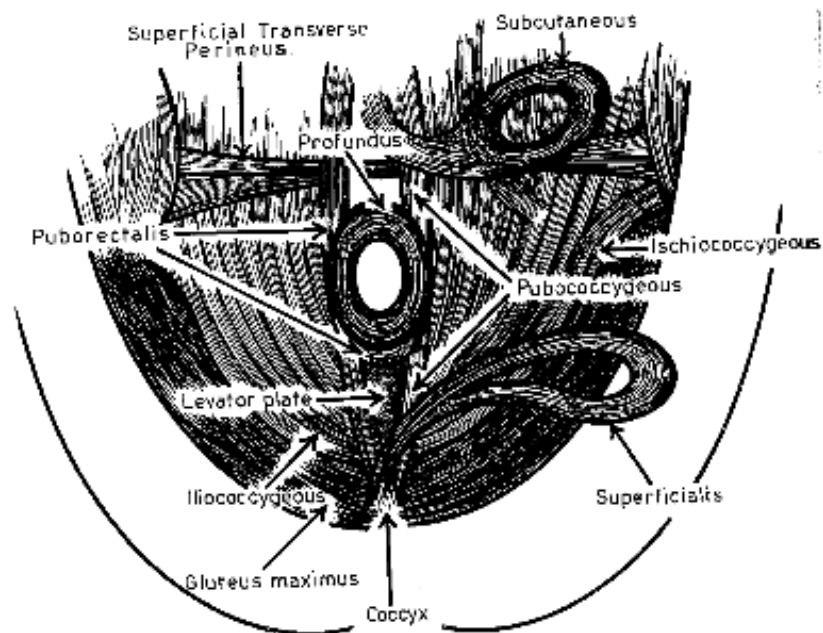


Figure. 11: This drawing shows the muscles, superficialis, and subcutaneous pulled laterally to show the profundus above and the levator plate.

Posteriorly, the puborectalis division of the levator ani reinforces the anal canal, and this forms the posterior and upper margin of the anorectal ring.

Anteriorly, it decreases until there remains only a thin sheath of reflector levator fibers called the Junction of Luschka. In the anterior quadrant, only the profundus portion of the external sphincter forms the anorectal muscle ring.

[top](#)

THE ANOCOCCYGEAL LIGAMENT OR BODY

This is a firm composite musculo-fascial structure extending from the posterior aspect of the anal canal to the tip and sides of the coccyx (Fig. 12), on the lower sacrum. Into it fuses the strong insertions of the glutei muscles, the ischiococcygeus, the pubococcygeus, and the puborectalis muscles, (all at different levels) the superficialis fibers, and finally, the terminal posterior extensions of the combined longitudinal muscle and superficial fascia.

Inferiorly it is bounded by the skin. Superiorly its fascial stratum is the supra anal fascia, which supports the rectal ampulla.

[top](#)

THE LEVATOR ANI MUSCLE

The levator ani is comprised of many muscular coalescing parts (Fig. 12). Four principal paired muscles forming the levator are described as the pubococcygeus, the puborectalis, the iliococcygeus and ischiococcygeus.

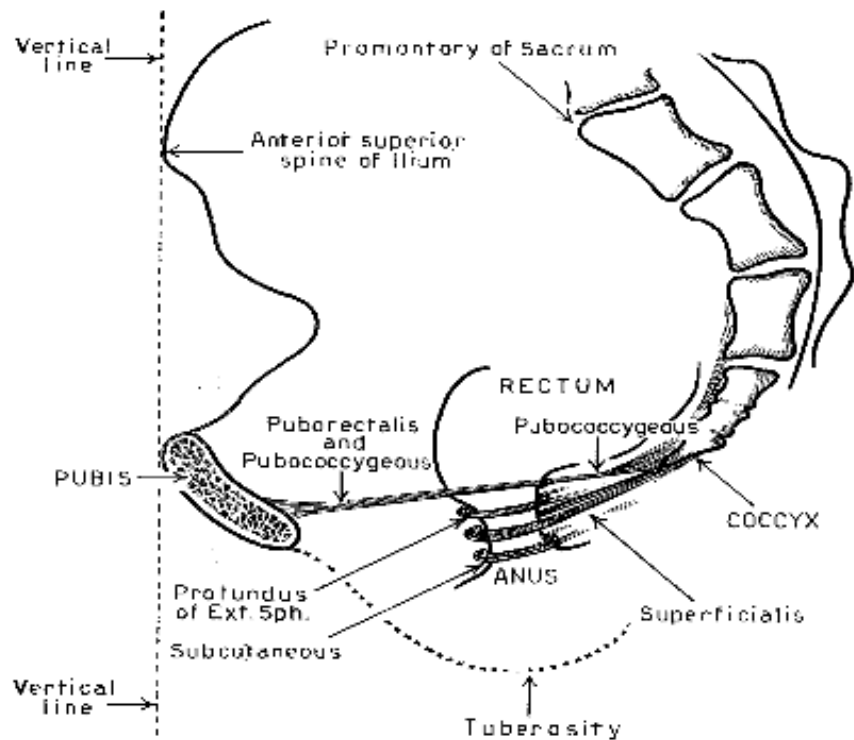


Figure 12: The vertical dotted line illustrates the plane relationship of the anterior limit of the pubis with the anterior, superior spine of the ileum.

[top](#)

The Pubococcygeus Muscle

The pubococcygeus (Fig. 9) has as its origin, a common origin with the puborectalis, the posterior surface of the pubic arch and the arcus tendineus. The main portion of the pubococcygeus continues posteriorly along with the puborectalis and is interlaced to a point of being inseparable, until the pubococcygeus passes around the rectum and continues to its insertion into the anococcygeal body, the coccyx, and the lower sacrum. Fibers of pubococcygeus intermingle with the fibroelastic extensions of the conjoined longitudinal muscle, to become part of the corrugator cutis ani.

[top](#)

The Puborectalis Muscle

This muscle (Fig. 9) arises practically in common with the pubococcygeus, but on a slightly lower plane. Owing to the fact that the puborectalis and pubococcygeus, as they pass posteriorly, the fibers intermingle and continue to do so until the puborectalis begins to swing on the posterior side of the rectum, to encircle the rectum and become part of the anorectal muscle ring. Damage to the puborectalis, more than any other of the anorectal muscle ring, may result in fecal incontinence.

[top](#)

The Iliococcygeus Muscle

The Iliac portion of the levator (Fig. 11) arises from the fascial covering of the obturator internus muscle and is directed posteriorly and medially, converging somewhat with the pubococcygeus as they conjointly insert into the coccyx and lower sacrum. This muscle supports the anorectal shelf in the act of defecation.

[top](#)

The Ischiococcygeus Muscle

This muscle (Fig. 11) is covered with the same fascial planes from the pubococcygeus and iliococcygeus. It originates from the ischial spine and adjacent sacro-iliac fascia. It attaches to the coccyx, the lower sacrum and the median portion of the sacro-tuberous ligament. The combined

levators fix the pelvic structures and present a fulcrum against which increased abdominal pressure may be exerted in the acts of lifting, coughing, defecation, urination, coitus, and various other activities.

[top](#)

THE PELVIC TRIANGLES

The pelvic outlet is commonly divided into the anterior and posterior triangles by an interischial line. The anterior triangles are the urogenital and urethral or genital. The posterior triangles are the anal, ischioanal or ischioanal. The anal and urethral triangles embrace all the structures of the pelvic floor, situated between the peritoneum and the skin.

The urogenital triangles, according to Gorsch, contain the following three superimposed musculofascial planes: 1) The superficial group, containing the bulbocavernosus, (accelerator urinae, sphincter vaginae and bulbospongiosus), the ischiocavernosus muscle and the superficial transverse perineal muscle. 2) The middle group, containing the deep transverse perineal muscle and the sphincter urethrae membranous muscle. 3) The deep group, containing the pelvic portions of the puborectalis and pubococcygeus muscles.

The anal triangles contain the following musculature: The external and internal sphincters, the levator ani with the ischiococcygeus muscle, making up the pelvic diaphragm, and the pyriformis muscle. It should be emphasized here that the deep muscular strata are closely interrelated with the sphincters. By supporting and fixing the pelvic diaphragm, the levators coordinate the activity of the sphincters.

[top](#)

THE PERINEOPELVIC SPACES

The perineopelvic spaces with their contained structures are directly concerned in the surgical therapy of hemorrhoids, fissure and fistulae. In several instances, the spaces are merely planes of cleavage between closely opposed fascial ensheathments of adjacent organs, as the prerectal, posterior prostatic, retrorectal, or rectovaginal spaces. These are all significant in that they are routes of infectious extensions.

[top](#)

The Perianal Space

According to Gorsch, this space surrounds the anus and the lower third of the anal canal. Its conformation depends upon the distribution of the fibro-elastic extensions of the conjoined longitudinal muscle. Below the lower margin of the internal sphincter, a prominent group of these extensions insert into the anal canal as the intermuscular septum. From this septum the extensions continue downward below the lining of the anal canal into the perianal skin. Here they fuse with the lateral extensions passing external to the subcutaneous muscle. The inner and outer extensions roughly bound a space, which contains the subcutaneous muscle and the external hemorrhoidal plexus of veins with their supporting areolar network. This is the perianal space. Laterally, this space is continuous with the ischioanal fossa. Posteriorly, it is designated as the post-anal space.

[top](#)

The Submucous Space

Directly above the anorectal line is the internal hemorrhoidal plexus of veins, which occupies the submucous space, extending proximally to the upper part of the columns of Morgagni. This space contains the venous radicals, a well-marked muscularis with loose areolar tissue, lymphatics, and arterial and venous capillaries. The pecten lies between the submucous and perianal spaces. This space is particularly important in hemorrhoidal formation.

[top](#)

The Ischioanal Fossae

The conformation of the ischioanal fossae (Fig. 13) depends upon the disposition of the levator ani muscle, which forms the inner wall and roof of the ischioanal fossae. Anteriorly, the fossae are bounded by Colle's fascia and the extensions of the fascial shelf along the posterior aspect of the

superficial perineal pouch and the triangular ligament posteriorly, the boundary of these fossae is formed by the gluteus maximus muscle and the sacrotuberous ligament.

In its posteriomedial angle, the fourth sacral nerve traverses the fossae for a short distance. The perforating branches of the second and third sacral nerves leave the fossa below the gluteus, about midway between the coccyx and the ischium. Posteriorly, a thin layer of fascia separates the two fossae. Communication between them usually passes directly behind the profundus. The deepest portion of the fossae is in the area of the ischial spines.

Inferiorly, the skin, reinforced by Milligan's Septum forms the roof of the fossae. It is either incomplete posteriorly or there are anomalous defects in the area which permit entrance of infection into the fossae. Posteriolaterally is the vascular pedicle containing the inferior hemorrhoidal artery, veins and nerves.

The lateral walls of the fossae are formed by the fascia of the obturator internus muscle. Behind the obturator fascia, surrounding the pudendal artery, vein and nerve is the old terminology, "Alcock's Canal" (Fig. 5).

The fossae are smaller, narrower and deeper in the male. The average fossae are from 6-8 cm anteroposteriorly, 2-4 cm in width, and 6-8 cm in depth. The contents then are: inferior hemorrhoidal veins and nerves crossing transversely; posteriorly, the perineal and perforating branches (cutaneous) of the pudendal plexus, and anteriorly, the posterior scrotal or labial vessels and nerves.

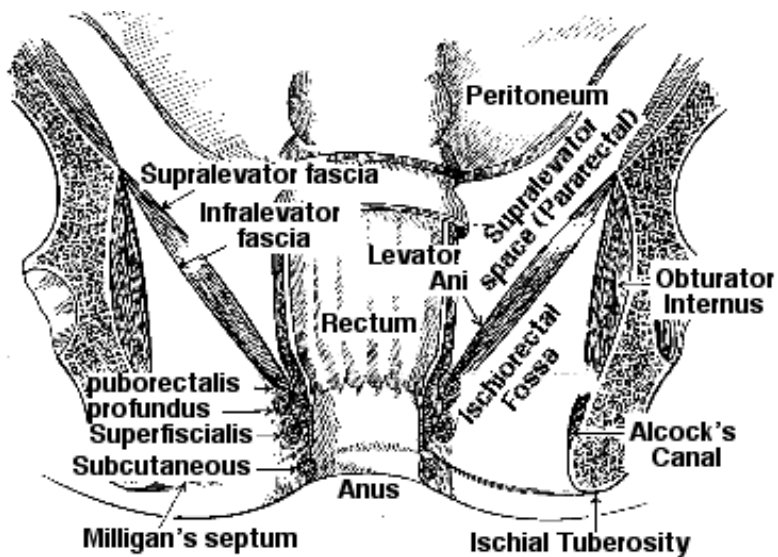


Figure 13: Ischioanal fossae and pararectal spaces.

[top](#)

The Supralelevator Spaces (pararectal)

According to Stanton, the supralelevator spaces (Fig. 13) lie on either side of the rectum, above the levator and below the peritoneal reflections of the abdominal cavity. These spaces are protected from infections by formidable fascial barriers. As the levator muscles join with the muscles of the rectal wall, the fascia blends with the rectal fascia. The supralelevator and infralevator fasciae are thus continuous with the fascial coverings of the rectum. The supralelevator spaces extend anteriorly to the prostate and seminal vesicles in the male, and to the uterosacral ligaments in the female. Infections in both sexes vary according to the conformation of the spaces.

[top](#)

The Retrorectal Space (Pre-sacral)

This space lies posterior to the rectum and anterior to the sacrum and coccyx (Fig. 14). It is lined

anteriorly by rectal fascia, posteriorly by the fascia of the sacrum and piriformis muscle, and inferiorly by the fascia of the structures of the rectal shelf. The retrorectal space is separated from the supralevator spaces by strong fascial concentrations, the rectal stalks. It is a potential space and has the potential of large capacity for infectious processes.

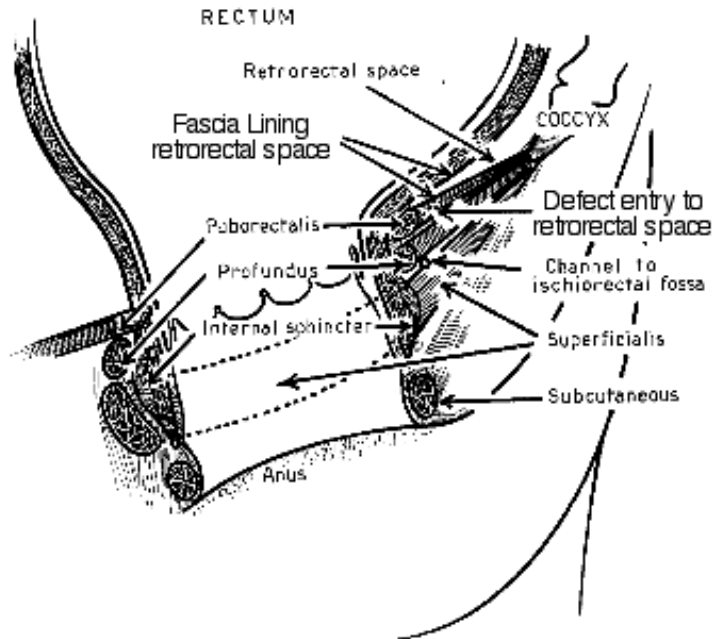


Figure 14: Retrorectal space.

top

The Rectovaginal Space

It is more or less a septum than an actual space, extending from the vesicovaginal peritoneal fossa above, to the perineal body below. This space is filled with a thin reflection of superficial fascia which forms a line of cleavage between the rectum and the vagina.

top

The Anococcygeal Triangle

The anococcygeal triangle (Fig. 15), as described by Stanton, lies in the sagittal plane posterior to the anal canal, anterior to the coccyx below the levator shelf, and above the skin of the gluteal cleft. This triangle is in the midline and between the posterior extensions of the pubococcygeus and the superficialis, and some posterior extensions of the puborectalis muscles. The vertical triangle is outlined as follows: A line drawn from the tip of the coccyx anteriorly to the midline point at the posterior margin of the profundus muscle; from this point, a second line extends downward in midline to a point immediately posterior to the posterior encircling portion of the subcutaneous muscle; the third side of the triangle is on a line joining the latter point with the tip of the coccyx. Gorsch describes the anococcygeal triangle as the posterior triangular space, which is divided into a superficial and a deep portion. The deep portion is situated above the superficialis, below and behind the puborectalis and profundus, and below the levator plate. It extends posteriorly to the coccyx and it is at point at which the ischioanal fossae communicate through the posterior communicating space.

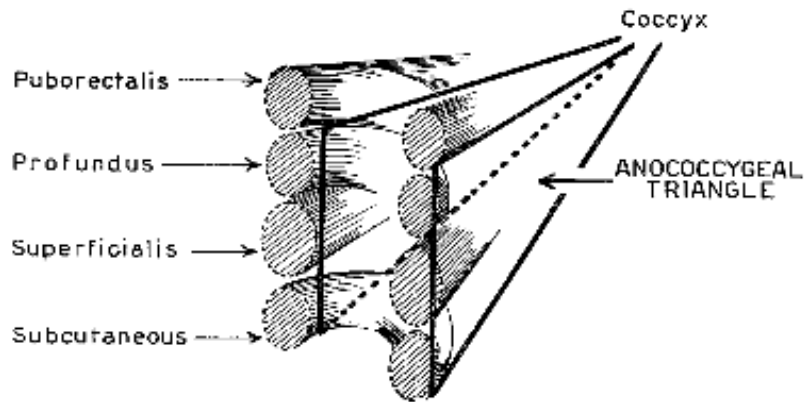
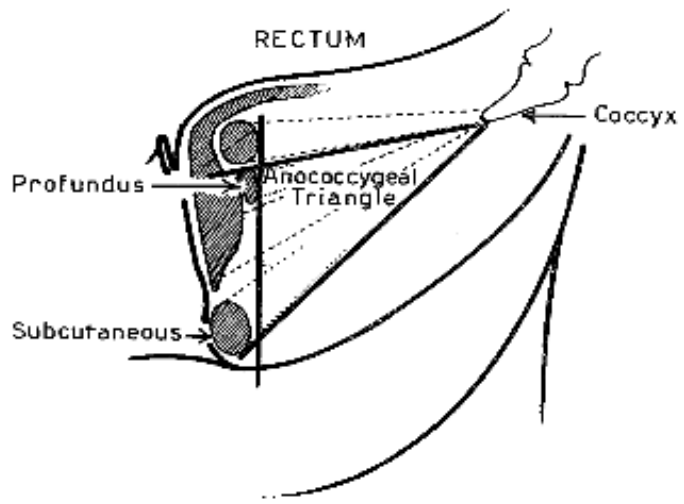


Figure 15: Anococcygeal triangle.

The anococcygeal triangle should not be confused with Minor's triangle (Fig. 16), which is a horizontal triangle of the skin.

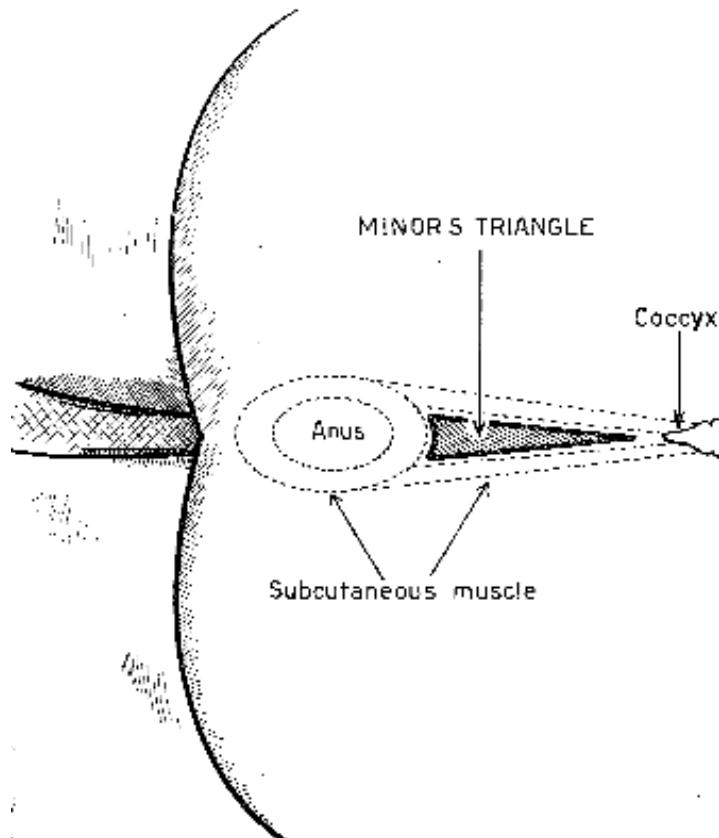


Figure 16: Minor's triangle.

top

THE BLOOD SUPPLY TO THE ANORECTAL REGION

Gorsch describes the arterial supply to the anal canal and the anal musculature as being somewhat distinct from that of the rectum, and to avoid confusion, separate discussion is necessary.

In general, the inferior hemorrhoidal artery supplies the posterior and the lateral aspects of the anal musculature and adjacent integument by superficial and deep branches, while a separate transverse perineal branch, usually arising independently from the pudendal, supplies the anterior aspect. Terminal branches of the above vessels supply the musculature at different levels, reaching the subepithelial areolar tissue of the anal canal (the pecten) and the annulus hemorrhoidalis of the rectum, anastomosing with the terminal radicals of the superior hemorrhoidal vessels and to a lesser extent, with the middle hemorrhoidal or inferior vesicle arteries. The larger branches of the vessels follow the fascial planes and define the separate divisions of the external sphincter.

The inferior hemorrhoidal artery, arising from the pudendal (Fig. 17), crosses the posterolateral aspect of the ischioanal fossa, en-sheathed in a reflection of the superficial pelvic fascia, which also includes the vena comites, a few lymphatics, and sometimes nerves (hemorrhoidal stalks). There may be one or more branches direct from the pudendal in addition to the main branches described as the inferior hemorrhoidal.

The inferior hemorrhoidal commonly divides into three main branches. The first, directed posteriorly and upward, to supply the adjacent portions of the obturator internus, gluteus maximus and levator ani muscles; the second, directed toward the posterior aspect of the anal musculature, gives off three smaller branches, one supplying the anococcygeal ligament and its musculature, a second supplying the posterior aspect of the anorectal musculature, and reaching the anal canal in the interval between the subcutaneous and the superficialis muscles just lateral to the posterior commissure; the third and largest branch is directed to the mediolateral aspect of the anal sphincters, supplying them at different levels by smaller branches, which finally reach the subepithelial musculature and anastomose with the branches of the superior and middle hemorrhoidals.

The anterior transverse perineal branch is usually a separate vessel, arising from the pudendal, conveniently termed "the anterior sphincterian artery". This vessel branches from the pudendal just before the latter gives off the perineal branch, which reaches the superficial perineal pouch, while the main trunk of the pudendal continues between the layers of the triangular ligament and deep perineal pouch, to supply the penis. The perineal artery reaches the anterior aspect of the anal canal, supplies the musculature and anastomoses with the anterior terminals of the inferior hemorrhoidal artery.

The middle sacral artery, coursing down the medial aspect of the sacrum behind the deep fascia, reaches the anococcygeal body, and supplies it and the coccyx, finally ramifying in the skin over the coccyx and the coccygeal ligament.

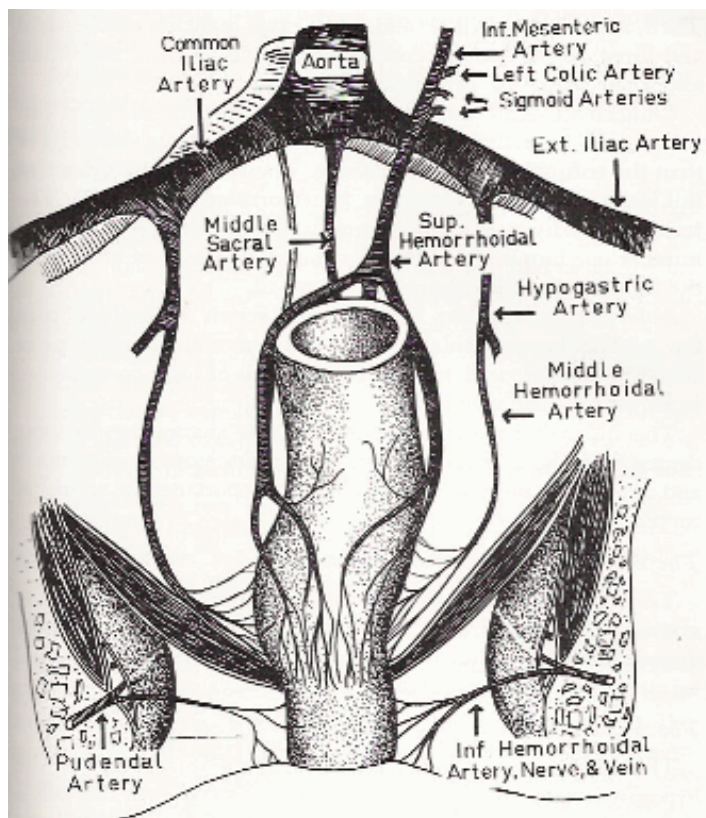


Figure 17: Blood supply of the anorectal area. Fascia propria, not shown here, encases the superior hemorrhoidal vessels (Fig. 5).

[top](#)

THE VASCULAR SUPPLY TO THE RECTUM

The vascular supply to the rectum is significant in the conception of internal hemorrhoids. The inferior mesenteric artery, below its last sigmoid branches, continues to the rectum as the superior hemorrhoidal (Fig. 17). The sigmoid branches are important in number and distribution. The superior hemorrhoidal artery accompanied by the same vein, runs in the subserous fascia of the mesorectum. Reaching the rectal wall at about the level of the second sacral vertebra, it divides into right and left main branches, which extend to the fascia propria of the rectum, but finally pierce the rectal wall to reach the submucosa.

After its main division, the right and left branches give off several secondary lateral branches, which ramify around the upper rectum, and piercing its musculature, reach the submucosa where there it is free to anastomose between their terminal capillaries and those of the corresponding veins.

The main branch of the right side continues downward and penetrates the rectal musculature about two inches above the anorectal line. Reaching the submucosa, it divides into an anterior and a posterior branch. The anterior continues to the annulus hemorrhoidalis undivided, while the posterior branch, after reaching the annulus hemorrhoidalis of the posterior quadrant, divides into smaller secondary branches, one of which, reaches the mid-lateral aspect and the other, the posterior midline of the annulus hemorrhoidalis.

The left main branch also pierces the rectal wall with its accompanying veins, and reaching the submucosa, divides into two fairly large terminals, an anterior branch reaching the annulus hemorrhoidalis in its left anterior quadrant, and one posterior, reaching the annulus hemorrhoidalis in the left posterior quadrant.

The vena comites follow the arterial distribution closely, and in the terminal rectum, their combined arteriovenous anastomotic capillary network, together with the inosculation from the inferior plexus, and to a slight degree from the middle hemorrhoidal vein, form the important internal or superior hemorrhoidal plexus.

Therefore, the primary internal hemorrhoids formed in the plexus are fairly constant in relation to the terminations of the larger arterial bundles. Well-developed internal hemorrhoids are then situated usually in the right anterior, right posterior and left lateral areas.

[top](#)

THE VENOUS SUPPLY OF THE RECTUM

Although the veins follow essentially the same course and give off branches corresponding to the arteries, they require additional description, because of their relation to the formation of hemorrhoids and external or perianal hematmata. At the anal verge, the inferior hemorrhoidal veins are prominent and form the indefinite plexiform arrangement, which is commonly referred to as the external hemorrhoidal plexus. Terminal branches from this plexus, anastomose in the pecten of the anal canal with the radicals of the venous plexuses of the superior hemorrhoidals. This anastomosis seems to be of minor consequence clinically.

[top](#)

THE LYMPHATICS

According to Gorsch, from the practical and clinical viewpoint, the lymphatics of the perineum, anal canal and rectum should be considered as a loose system in which free anastomosis and overlapping occur.

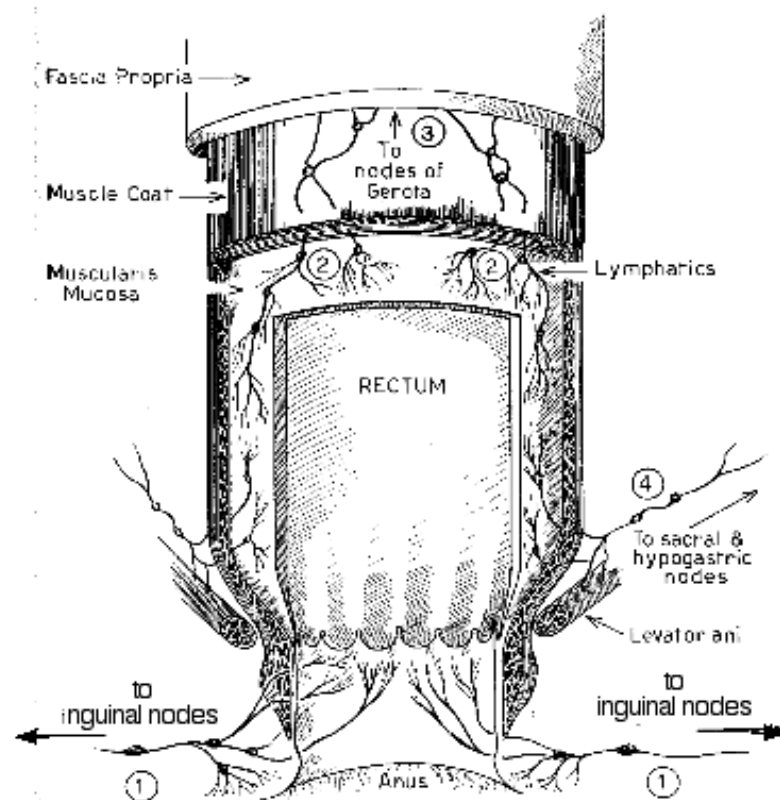


Figure 18: The lymphatic vessels of the anorectal area.

[top](#)

Anorectal Lymphatics

These are divided as follows:

1. Perianal Group
2. Anorectal Group (anal and rectal portions)
3. Extrarectal Group

[top](#)

Perineal Group (Cutaneous System or Inferior)

This group drains the superficial and deep layers of the perineal skin (No. 1, Fig. 18). The afferent collecting trunks follow in general, the perineoscrotal or labial folds, and terminate in the inferolateral group of inguinal nodes. There is much overlapping with the lumbar and gluteal plexuses.

[top](#)

The Anorectal Group

The Anal Portion: Three plexuses of the anal canal and the sphincteric portion of the rectum are demonstrable. They are the mucosal, submucosal and intermuscular.

The mucosal and submucosal sets (No. 2, Fig. 18) are continuous with those of the rectum proper and extend through the anal canal to anastomose with the perineal plexus, draining into the inguinal nodes. The submucosal ramifications are particularly rich in the columns of Morgagni, and there are probably both afferent and efferent channels from these zones.

The intermuscular plexus lies between the circular and the longitudinal muscle coats and extends into the adjacent ischiorectal fossae. Much overlapping is present at the level of the internal sphincter, making the true anatomic course of a single plexus very difficult to follow. Lymph flow may be reversible.

The Rectal Portion: The rectal portion of the anorectal group is similar to that of the sigmoid with the same division of plexuses and free anastomosis. These plexuses communicate with the extrarectal group of lymphatics. The lymph sinus of the rectum and the submucous plexus bears an important relation to the pelvic superficial fascia in the supralelevator and retrorectal spaces. Afferent and efferent lymphatic channels from these plexuses reach the extensive network of the extrarectal group.

[top](#)

The Extrarectal Group

The downward zone includes afferent lymphatics, which arise in the anal canal and rectal ampulla, and extending lateralward and downward, may involve the anal sphincters or tissues of the ischiorectal fossae. They spread along the ramifications of the inferior hemorrhoidal vessels, to reach the obturator fascia and the hypogastric nodes (No. 4, Fig. 18). The perianal skin may also be considered an important location in the lower zone.

The lateral zone embraces the entire ramifications of the subserous or superficial fascia between the pelvic wall, the levators, and the peritoneum above.

The upward zone includes the lymphatics and tissues in the retrorectal space with the important Nodes of Gerota (No. 3, Fig. 18), from which secondary lymphatics extend to those of the mesorectum and sigmoid, and drain into the intercolated nodes or those of the paracolic, iliac, and aortic groups.

The majority of the lymphatics from the rectal lymph sinus either pass through or drain into nodes contained in this zone, and is therefore, most important from the standpoint of metastasis of cancer.

[top](#)

THE NERVE SUPPLY TO THE ANORECTAL REGION

In general, the nerve supply is divided into two systems; the somatic or cerebrospinal system, which supplies nerve innervation to skeletal muscle, and nerve sensory innervation to joints, skin, and scalp, and the autonomic system. The autonomic system is subdivided into three groups; the medullary group (craniobulbar), the thoracolumbar, and the sacral group. Gorsch states that the thoracolumbar is sympathetic, while the medullary and the sacral subgroups are parasympathetic.

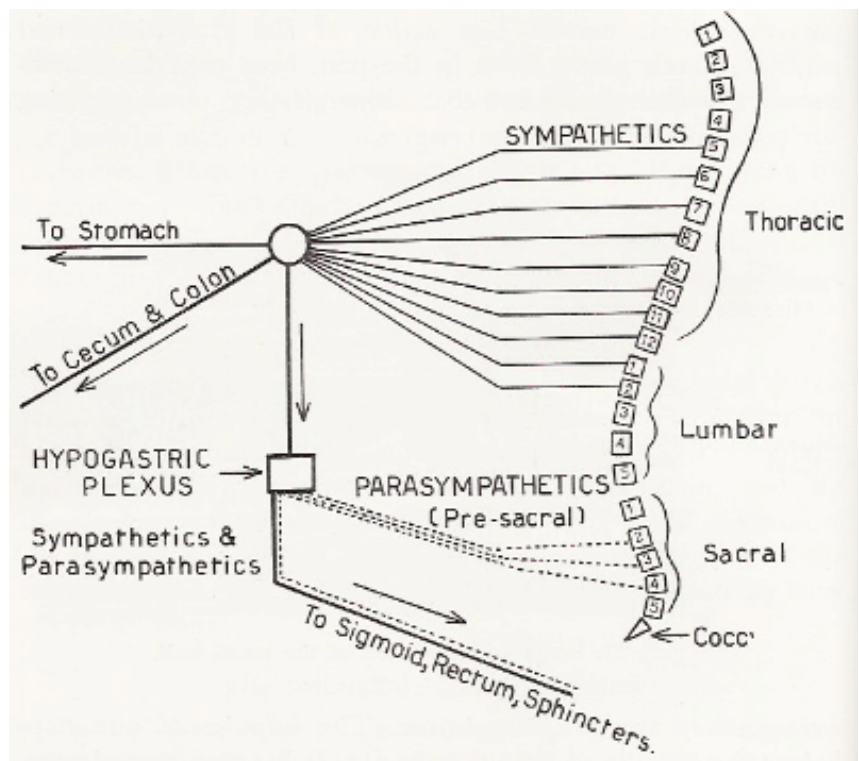


Figure 19: Schematic drawing showing the sympathetic and parasympathetic nerve supply to the sigmoid.

From a practical viewpoint, the sympathetic portion stimulates smooth muscle, causing vasoconstriction, contraction of the sphincters, and inhibition to peristalsis. In the urinary bladder and the rectum, it causes contraction of the sphincters, and inhibition of the detrusor musculature.

The medullary (craniobulbar) and the sacral outflows are secretomotor to the glands, motor to the musculature of the gut, and inhibitory to the cardiac, pyloric, and ileocecal sphincters, largely through the vagus. Afferent fibers convey vesicle sensibility from the alimentary tract to the ganglion nodosum of the vagus. The sacral outflow of the parasympathetics supplies motor fibers to the musculature of the distal colon and the rectum, the rectosigmoid junction and possible inhibitory fibers to the internal anal sphincter. The sympathetic distribution is similar to the cerebrospinal nerves.

In the pelvis, the essential sympathetic supply consists of the hypogastric plexus, which is subdivided into the superior, middle, and inferior plexuses.

The superior plexus is commonly referred to as the presacral nerve. It is formed by the continuation of the intermesenteric nerves, supplemented by branches from the lumbar sympathetic chain. It extends from the bifurcation of the aorta to the level of the promontory of the sacrum. Continuing into the pelvis, the plexus divides into the hypogastric branches (the middle plexus), which follows the hypogastric arteries, and terminates in the large: secondary plexus (the inferior plexus). This is situated at the level where the superior hemorrhoidal artery leaves the hypogastric in the lateral aspect of the pelvirectal space. Small secondary plexuses continue and join with the ganglionated chain along the sacrum and coccyx, to form the Ganglion Impar. Fibers from the inferior mesenteric plexus mingle with the above.

Parasympathetic (Nervi erigentes) reach their pelvic destination via the second, third, and fourth sacral spinal nerves. So far as the actual termination of these fibers can be determined in the visceral walls, it appears that the sympathetics terminate in the glands, while the parasympathetics end in small ganglia in the muscularis of the viscera.

Innervation of the anal canal and its musculature is derived from the cerebrospinal sympathetics and parasympathetics (Fig. 19).

Cerebrospinal innervation, sensory and motor, is the second, third, and fourth sacral and smaller coccygeal spinal filaments. These are distributed by the peripheral nerves, which reach the anal musculature and squamous lining of the anal canal and surrounding tissues through the inferior

hemorrhoidal nerve, the anterior sphincterian nerve, perineal branches of the fourth sacral nerve, and the coccygeal filaments.

Inferior hemorrhoidal nerves are branches of the pudendal (Fig. 20) and follow the distribution of the arterial branches. They supply the three divisions of the external sphincter and the terminal filaments in the skin, or continue to the anorectal junction.

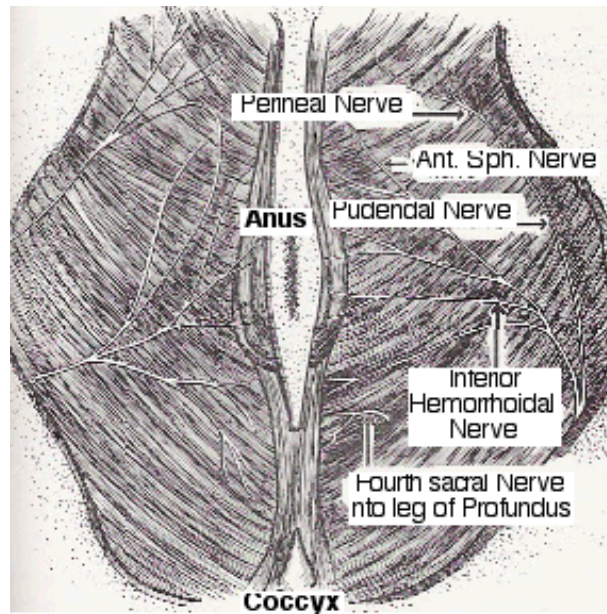


Figure 20: Pudendal nerve and branches. Fourth sacral nerve.

The anterior sphincterian nerve arises independently from the pudendal, goes transversely and supplies the anterolateral aspect of the anal musculature and adjacent tissues.

The perineal branch from the fourth sacral nerve pierces the coccygeus muscle and innervates the perianal skin (Fig. 21).

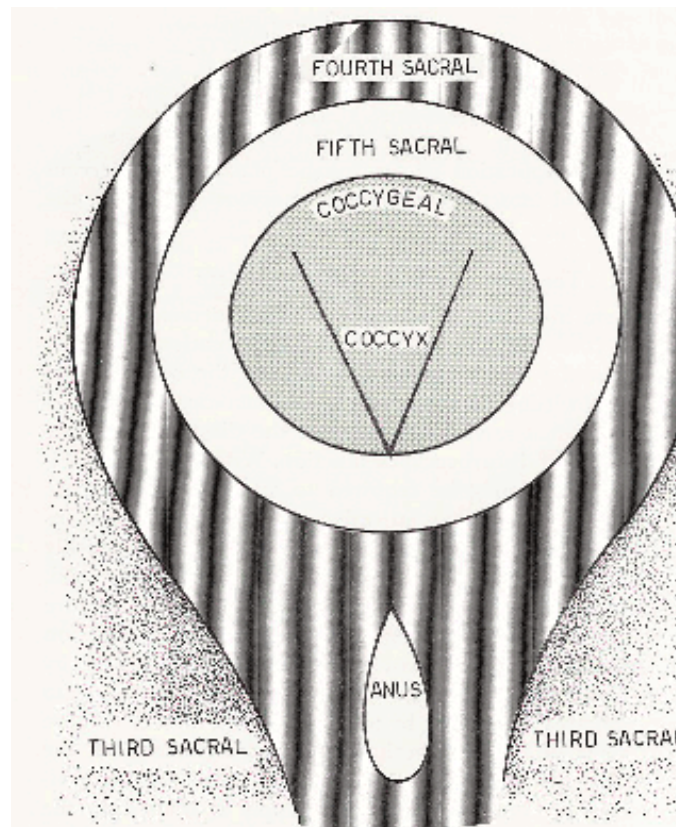


Figure 21: Diagram showing areas supplied by the sacral nerves.

The coccygeal spinal filaments are distributed anteriorly and posteriorly. The posterior ramifies over the coccygeal skin and inosculates with the dermal branches of the fourth sacral. The anterior filaments ramify in the anococcygeal body and skin.

Sympathetic innervation to the lower rectum and anal canal, and its musculature is mainly from three sources:

1. From the superior hypogastric plexus (Presacral Nerve) via the inferior hypogastric plexus, sympathetic fibers follow the branches of the middle hemorrhoidal arteries to be distributed around the anorectal junction. Visceral branches from the spinal nerves, also reach the inferior and superior hypogastric plexuses and have similar distribution (Viscerosacral nerves).
2. Sympathetic fibers from the inferior mesenteric plexus are also distributed with the terminal branches of the superior hemorrhoidal arteries, reaching particularly the annulus hemorrhoidalis of the lower rectum, and continuing through the pecten to reach the anal canal and perianal skin.
3. Sympathetic fibers, which are also carried by the inferior hemorrhoidal nerves, are parietal sympathetics arising from the sacral and coccygeal ganglionated cord, which supply the glands and vessels of the skin surrounding the anal canal.

The terminal distribution of the sympathetics to the rectum consists of the two plexuses of Auerbach and Meissner.

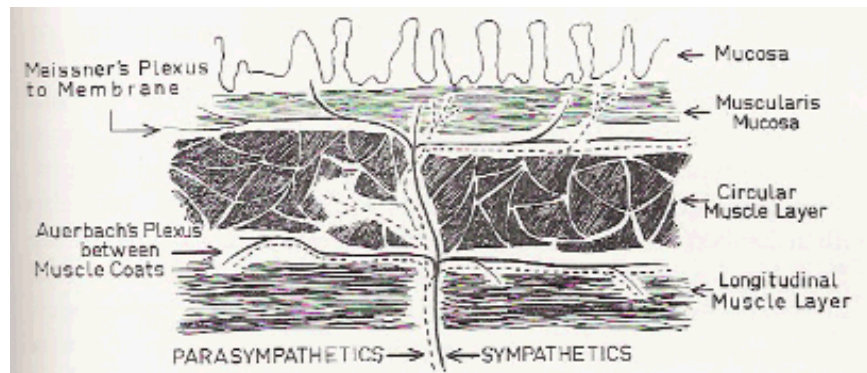


Figure 22: Schematic drawing showing Auerbach's and Meissner's plexuses in the wall of the bowel.

The plexus of Auerbach (intermuscular plexus) ramifies between the circular and longitudinal musculature of the rectum (Fig. 22), and continues in the conjoined longitudinal muscle to reach the perianal skin (sympathetic).

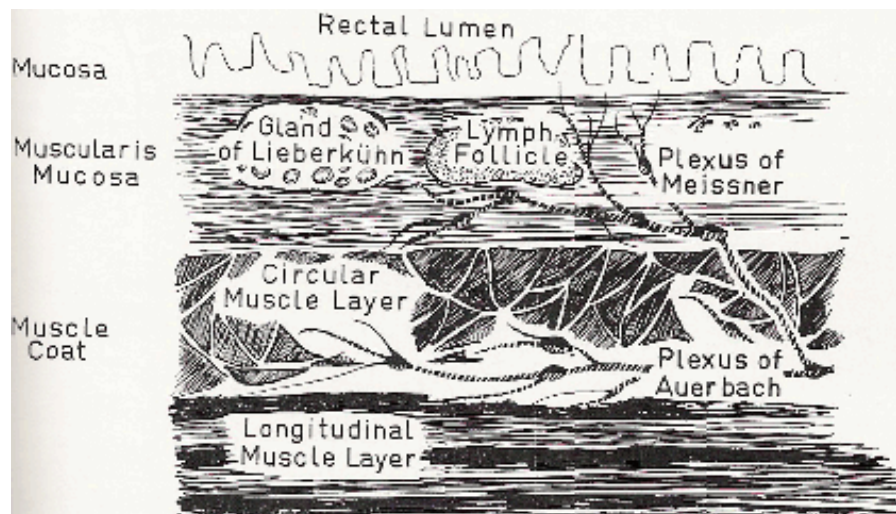


Figure 23: Longitudinal section of the rectal wall.

The plexus of Meissner (submucous plexus) is distributed through and innervates mainly the glandular

apparatus of the mucosa (Fig. 23). It ramifies in the submucosal layer of the rectum and is disposed around and between the glands, continuing down to reach the sweat, sebaceous, and apocrine glands of the perianal skin (parasympathetic).

[top](#)

NEUROPHYSIOLOGY (Defecation Reflex)

Physiologically, Gorsch states that defecation is best explained on the basis of a modified somatic autonomic reflex, normally under cortical control, and in which the desire to defecate may be conveniently distinguished from the act of defecation. The so-called "trigger zones" at which the initial sensory stimuli arise and produce the desire to defecate, are probably in the rectal musculature as well as in the anorectal line, which is the more important trigger zone. Threshold stimuli arise normally from the anorectal junctional area and are conveyed by the spinal sensory nerves, to initiate the active phase of defecation. The distention of the rectal wall also gives rise to some extent, to the desire to defecate through the sympathetic afferent nerves. This results reflexly, in a relaxation of the anal sphincters, particularly the internal, and a contraction of the rectal musculature. The act may be inhibited by the will.

On the other hand, voluntary relaxation of the anal sphincters with voluntary contraction of the colon and its complimentary muscles, with the expulsion of the rectal contents, is the actual act of defecation.

In adult life, defecation is no longer a reflex, but normally becomes a voluntary act, once the summation of sensory stimuli is effected. It becomes a purely reflex act, however (sympathetico-parasympathetic), in the autonomic innervated rectum, following destruction of its cerebral connections.

The broad subject of constipation is directly related to the sensorimotor response of the entire gastrointestinal tract as well as those of the rectum.

"Trigger zones" may be entirely extrarectal and in pathologic conditions, provoke a constant tenesmus leading to rectal prolapse. Further, the sensory and motor dispersions, before, after, and during the act of defecation are complex and may be reflected throughout the entire nervous system, e.g., fainting, abdominal cramping, orgasms, and neurocirculatory phenomena, are common clinical observations.

Defecation may also be entirely a cortical response. Central stimulation of the Vagus produces the defecation reflex, a contraction of the rectum and a relaxation of the anal sphincters.

In this regard, it may be observed that the segmental movements of the intestines are considered myogenic in origin, and the intrinsic plexuses of Meissner and Auerbach control that peristalsis (Fig. 22). The autonomic system (sympathetic and parasympathetic) subserves a regulatory function. Diarrhea may be entirely an intrinsic myogenic basis.

[top](#)

BIBLIOGRAPHY

Noll, Carlton M. Procto-Basics. Medicus Publications, 1978, pp. 07-44.

Stanton, Frank D. Newer Concepts in Clinical Proctology. Clinton Massachusetts: The Colonial Press Inc., 1958, pp. 05-45.